



# Pancreatic cancer: What defines resectability and the role for surgery

Douglas B. Evans

For the Multidisciplinary Pancreatic  
Cancer Study Group

The University of Texas

M. D. Anderson Cancer Center

Houston, Texas

September 20, 2008

THE UNIVERSITY OF TEXAS  
MD ANDERSON  
CANCER CENTER  
*Making Cancer History™*

# Multidisciplinary Clinical Working Group

## Surgery

Peter Pisters  
Jeff Lee  
Jason Fleming  
Nick Vauthey  
Eddie Abdalla

## Medical Oncology

Jim Abbruzzese  
Robert Wolff  
Gauri Varadhachary  
Mike Fisch  
Milind Javle  
David Fogelman

## Radiation Oncology

Chris Crane  
Sunil Krishnan  
Prajnan Das

## Pathology

Huamin Wang  
Gregg Staerkel

## Diagnostic Imaging

Eric Tamm  
Chusilp Charmsangavej  
Lisa Lano  
Priya Bhosale  
Aparna Balachandran

## Gastroenterology

Jeffrey H. Lee  
Manoop Bhutani

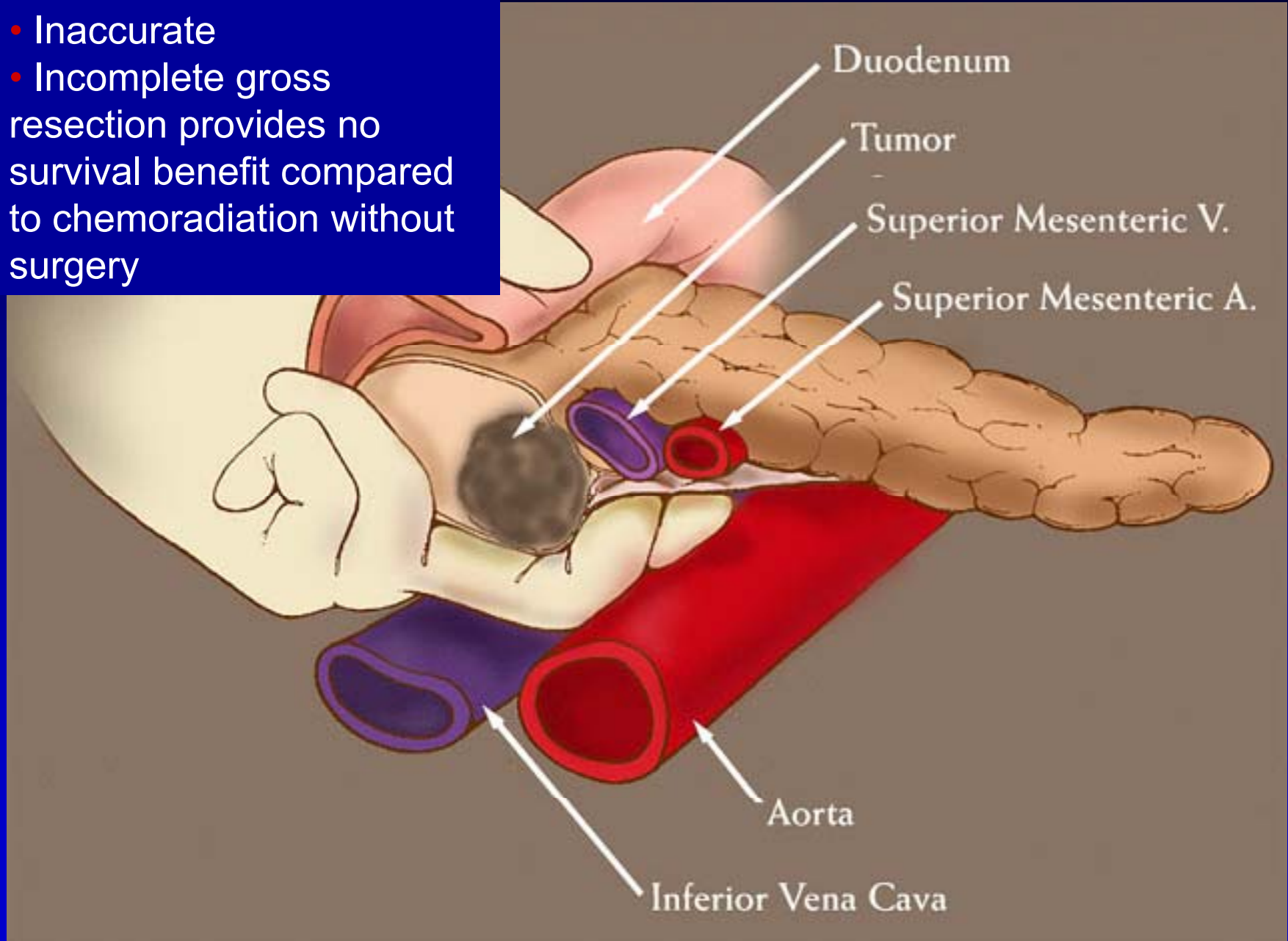
# Stage-specific survival

	Months From Dx
All patients	9.3
Stage I, II	15.4
resected	24.1
not resected	10.3
Stage III	9.9
borderline	17.6
Stage IV	6.1

MDACC: Pancreatic Cancer Program Database 1991-2007, N = 4,395  
Katz MHG, Hwang RF, et al. TNM staging of pancreatic adenocarcinoma.  
CA Cancer J Clin. 2008;58(2):111-25.

# Intraoperative Assessment of Resectability

- Inaccurate
- Incomplete gross resection provides no survival benefit compared to chemoradiation without surgery



SMA Margin  
(Retroperitoneal/uncinate)

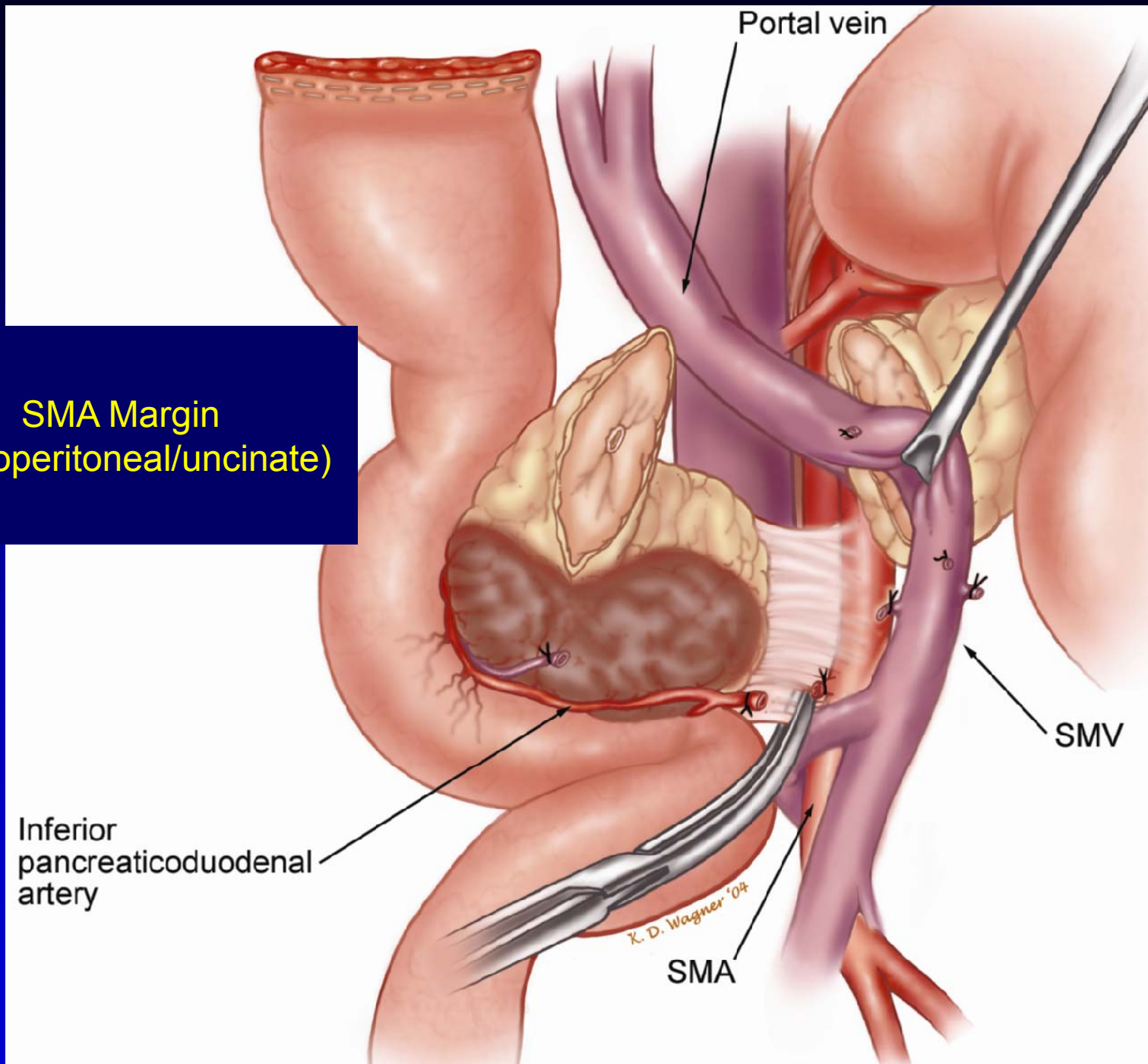
Inferior  
pancreaticoduodenal  
artery

Portal vein

SMV

SMA

*K. D. Wagner '04*



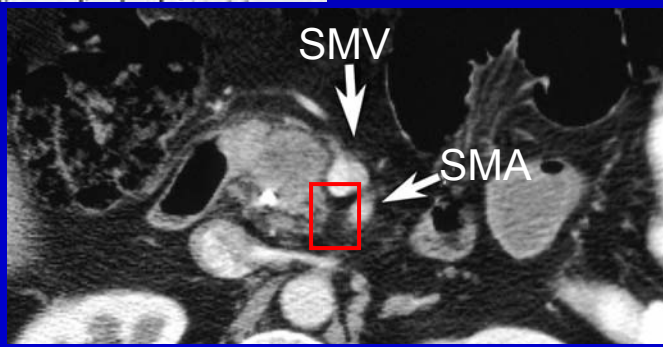
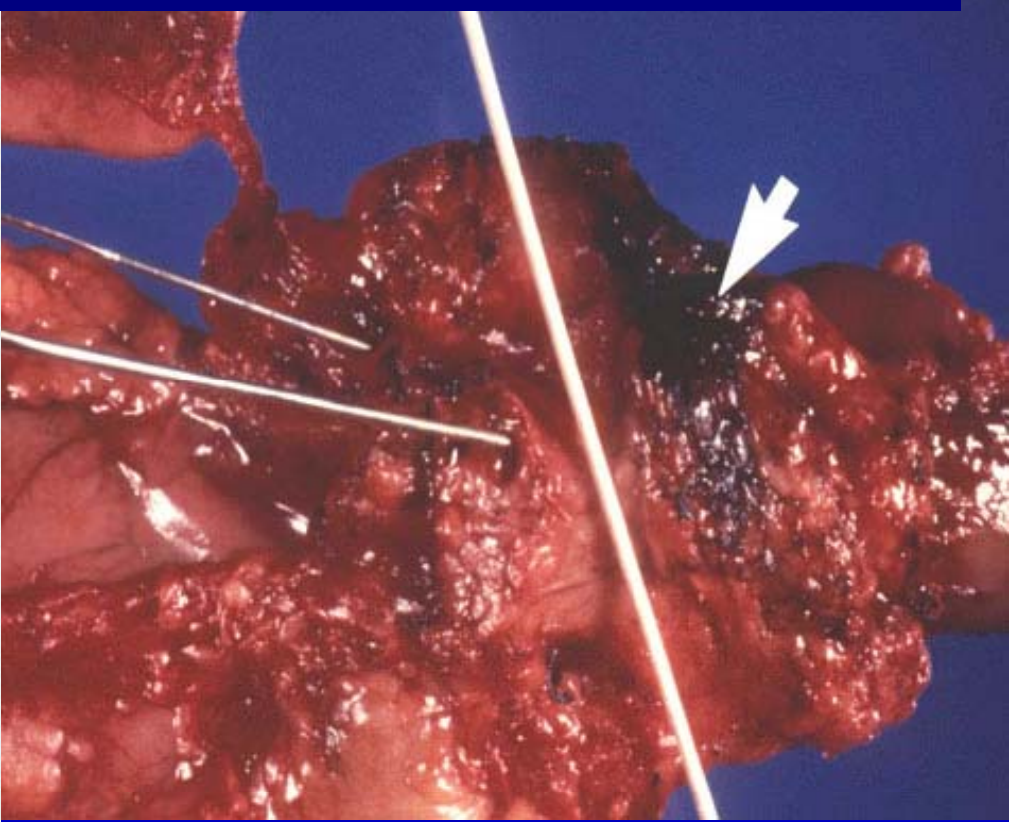
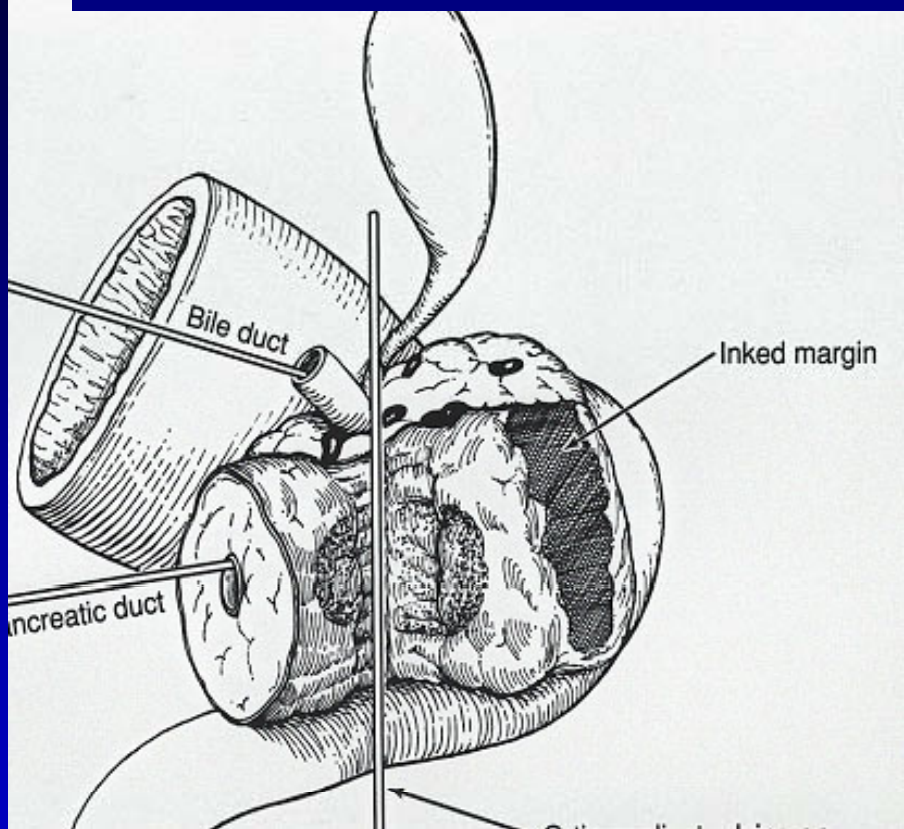
# ? Complete Resection

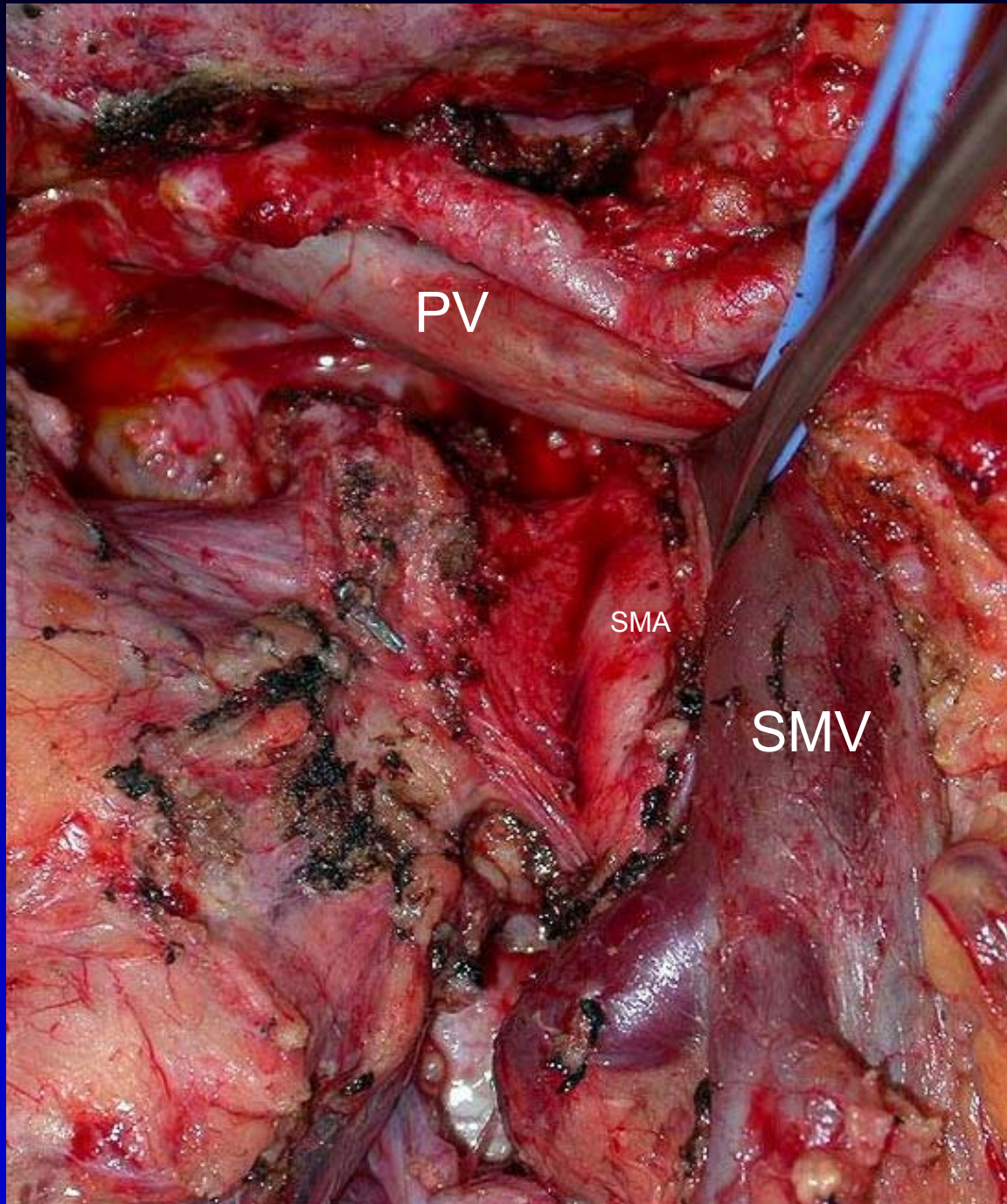
## R Status

R Designation	Gross Resection	Microscopic Margin
R0	complete	negative
R1	complete	positive
R2	incomplete	positive

Exocrine Pancreas. *In* Greene FL, Page DL, Fleming ID, et al., eds. AJCC Cancer Staging Manual. Chicago, IL: Springer, 2002. pp. 157-164.

# SMA (Retroperitoneal) Margin AJCC Cancer Staging Manual 6<sup>th</sup> Edition





PV

SMA

SMV

## SYNOPTIC REPORT

Specimen: Pancreaticoduodenectomy

Tumor Diagnosis: **DUCTAL ADENOCARCINOMA**

Degree of Differentiation: Moderate

The tumor size is 2.8 cm in diameter

Extrapancreatic extension present

Lymphovascular present

Perineural invasion present

**SMA margin uninvolved** with distance of 18mm to inked margin

Bile duct margin uninvolved

Pancreatic transection margin uninvolved

Proximal stomach or duodenum margin uninvolved

Distal duodenum or jejunum margin uninvolved

Regional Lymph Nodes:

**Total number involved: 3**

**Total number examined: 30**, including hepatic artery and periaortic

(Parts A and B)

Vessels removed: None stated

Final pTNM Staging (AJCC 6th edition):

**pT3** Tumor extends beyond the pancreas

**pN1** Regional lymph node metastasis

**pMX** Distant metastasis cannot be assessed

# Definitions

## Resectable:

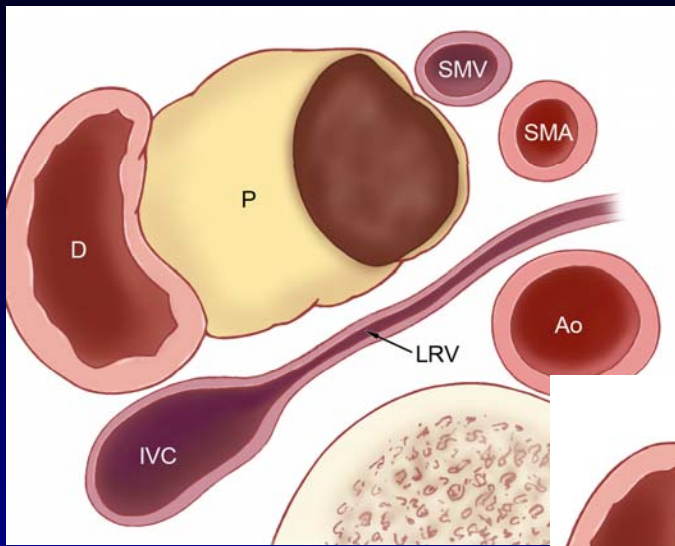
no extension to celiac, CHA, SMA  
patent SMV-PV confluence  
stage I, II (T1-3, Nx, M0)

## Locally Advanced:

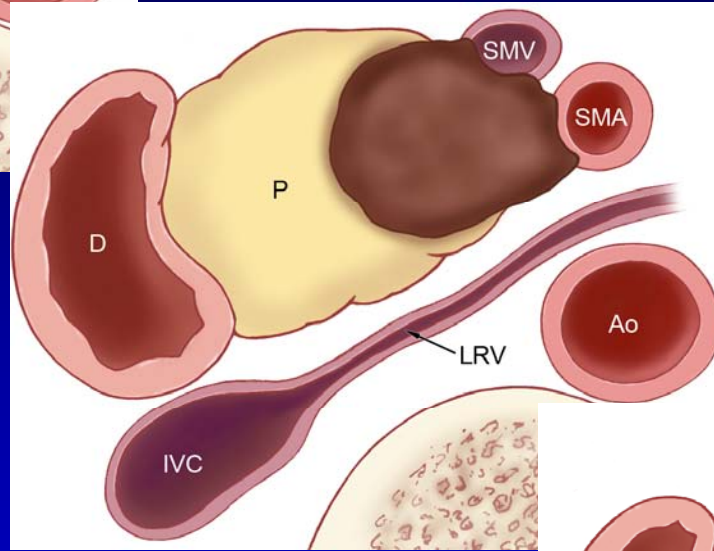
celiac, SMA encasement ( $> 180^\circ$ )  
stage III (T4, Nx, M0)

## Borderline:

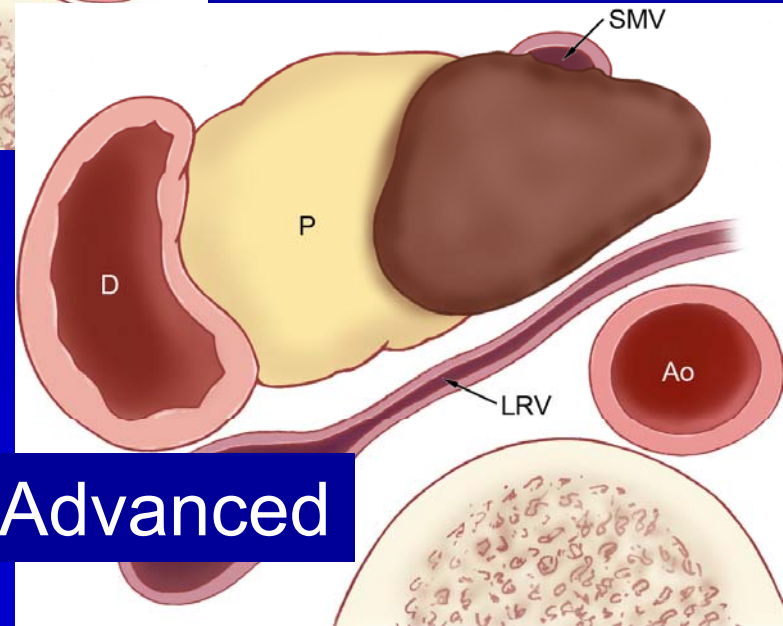
arterial abutment ( $\leq 180^\circ$ )  
stage III (minimal T4)



Resectable



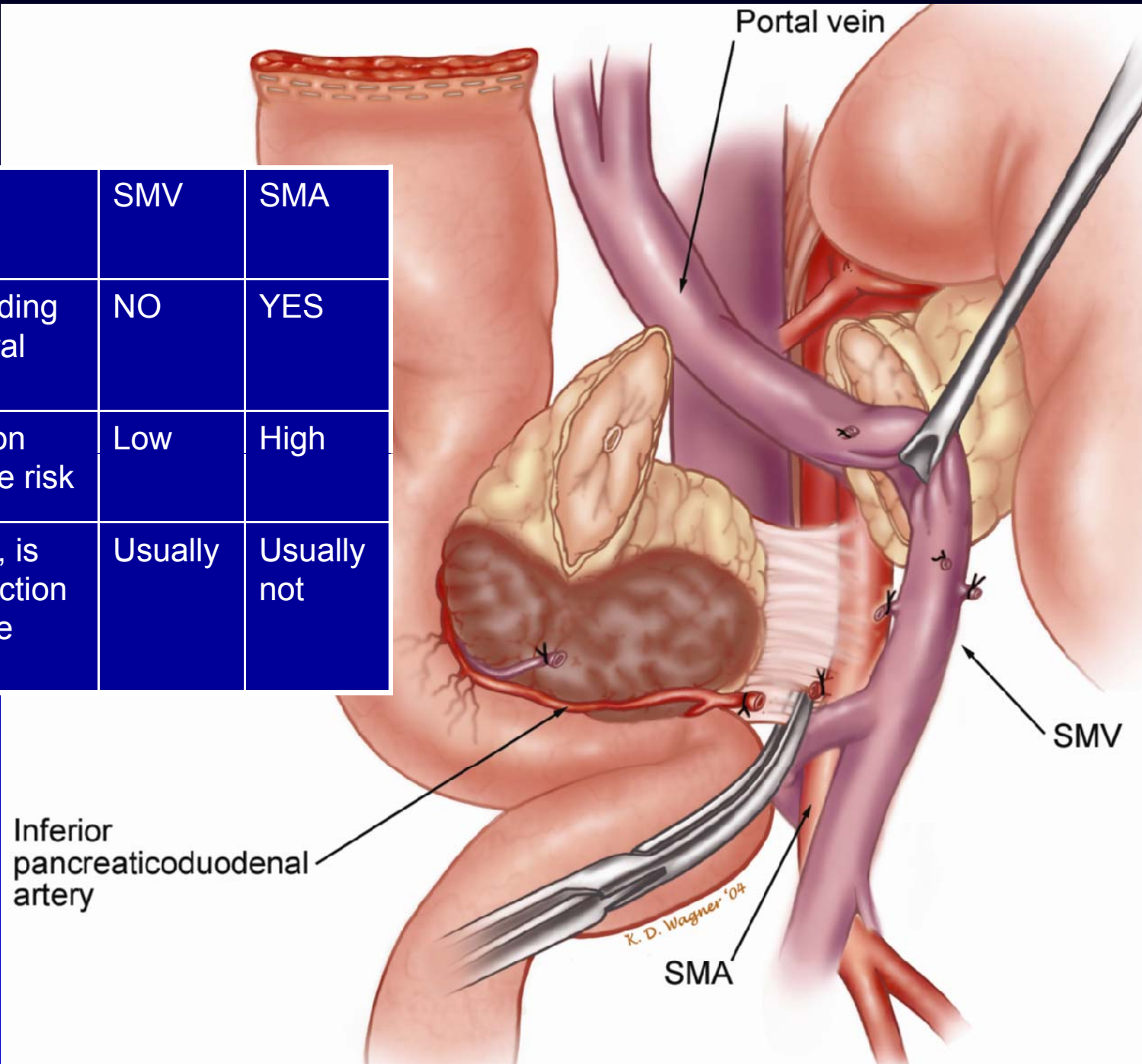
Borderline Resectable



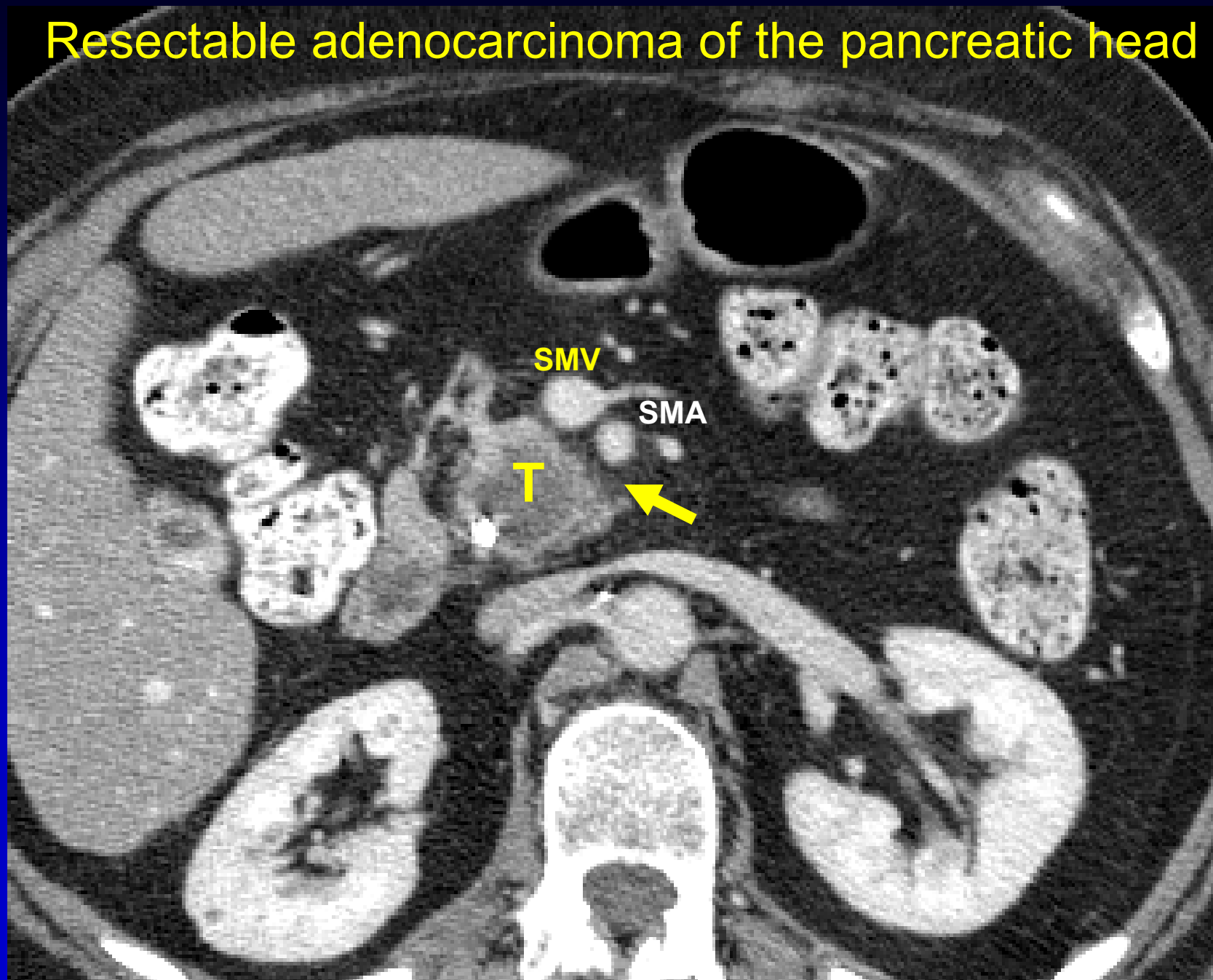
Locally Advanced

Courtesy of R Wolff, MD

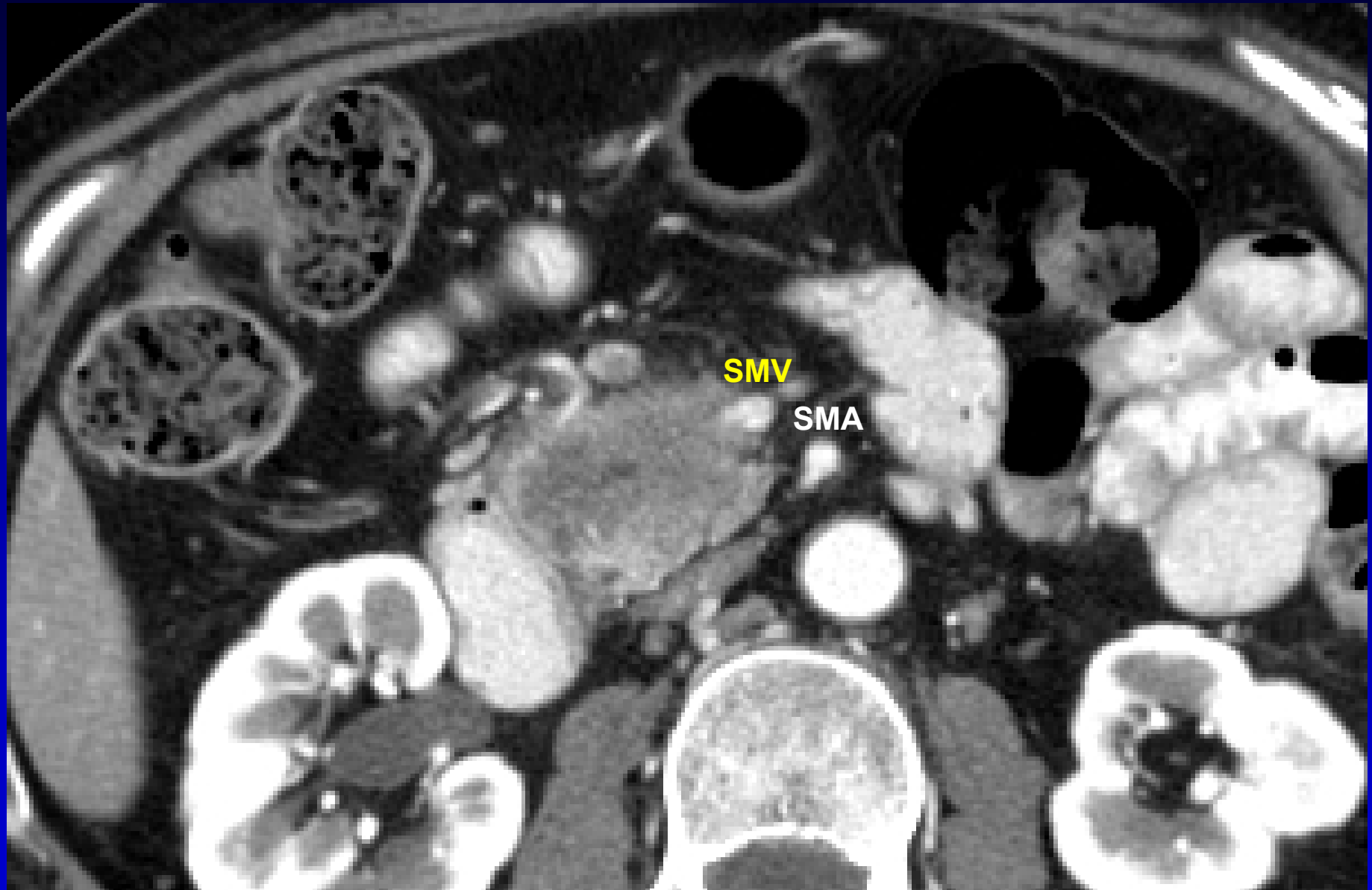
	SMV	SMA
Surrounding perineural plexus	NO	YES
Resection operative risk	Low	High
If resect, is the resection complete (R0)	Usually	Usually not



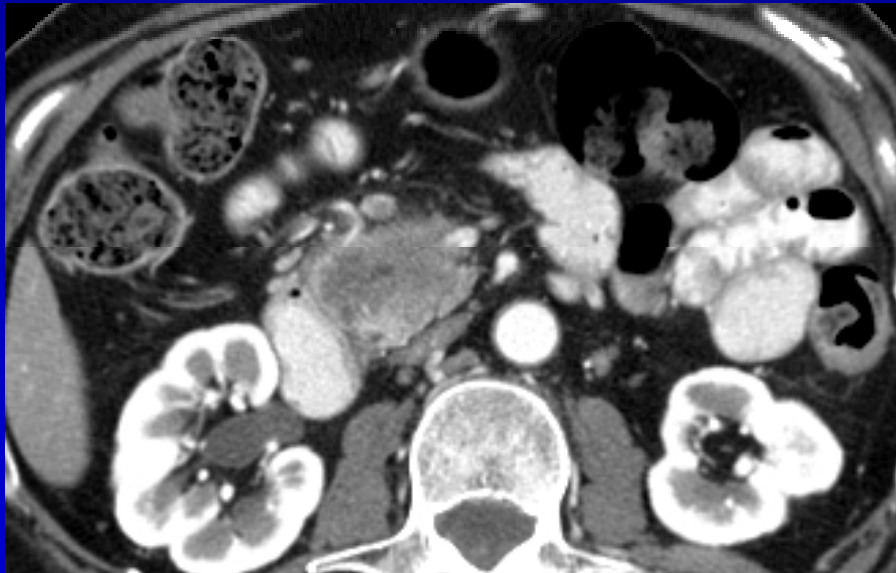
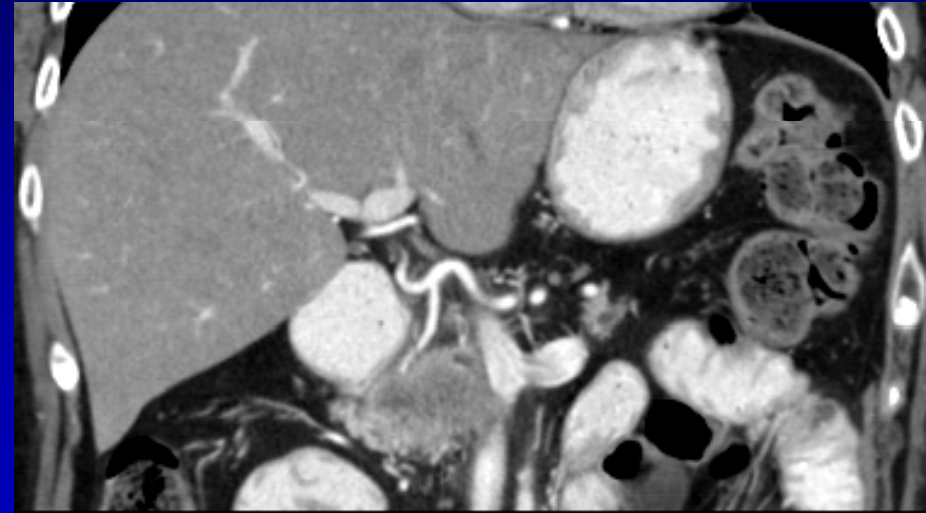
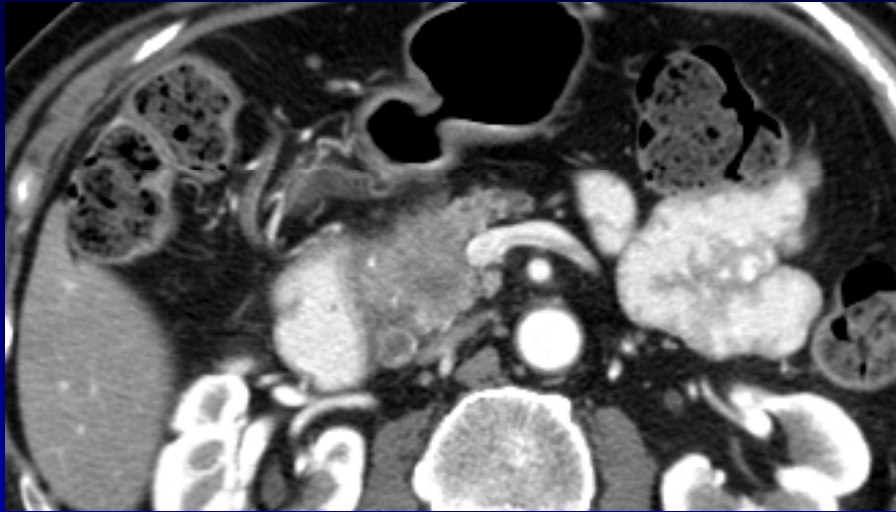
# Resectable adenocarcinoma of the pancreatic head



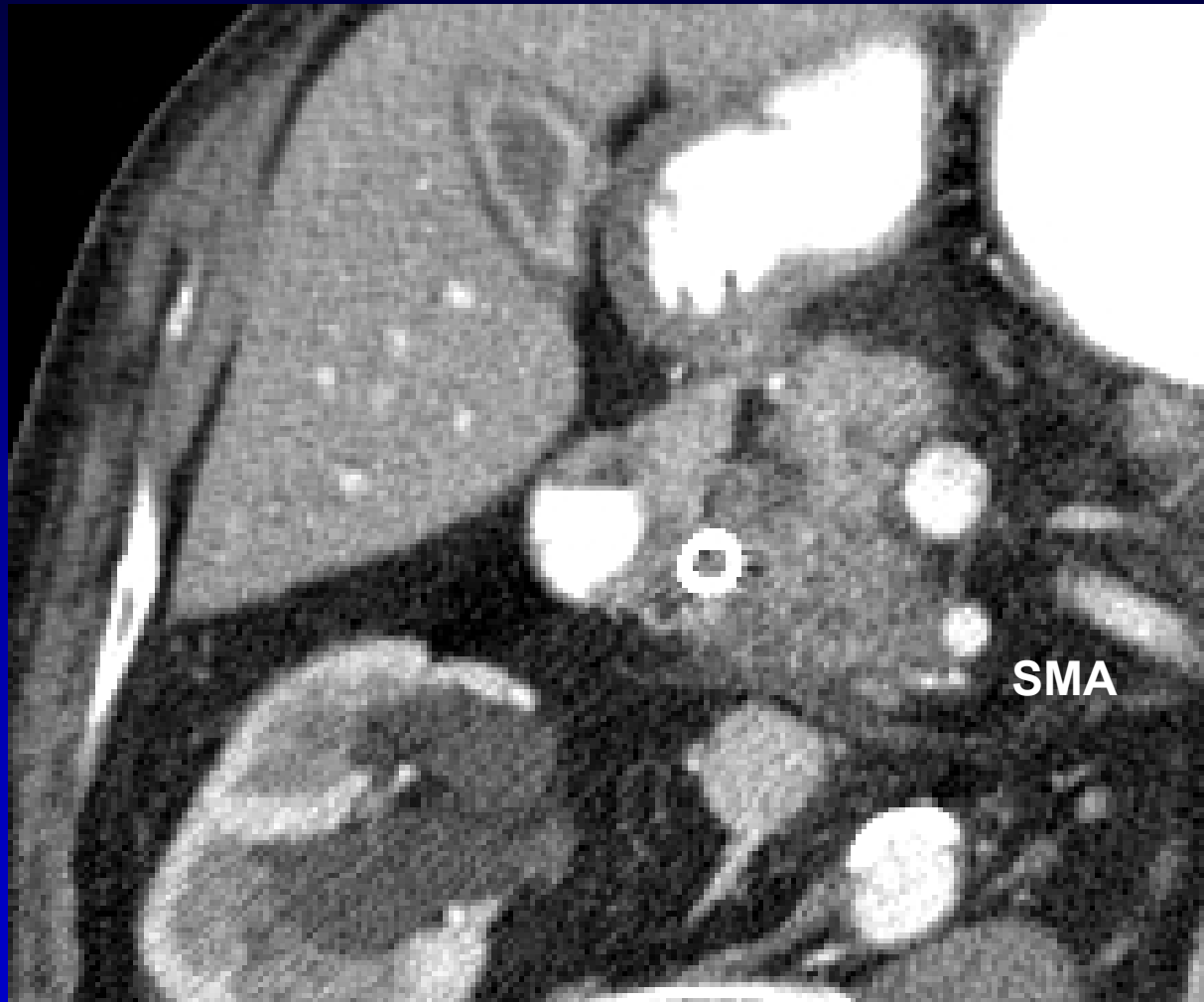Resectable : likely to require venous resection



**Resectable : likely to require venous resection**



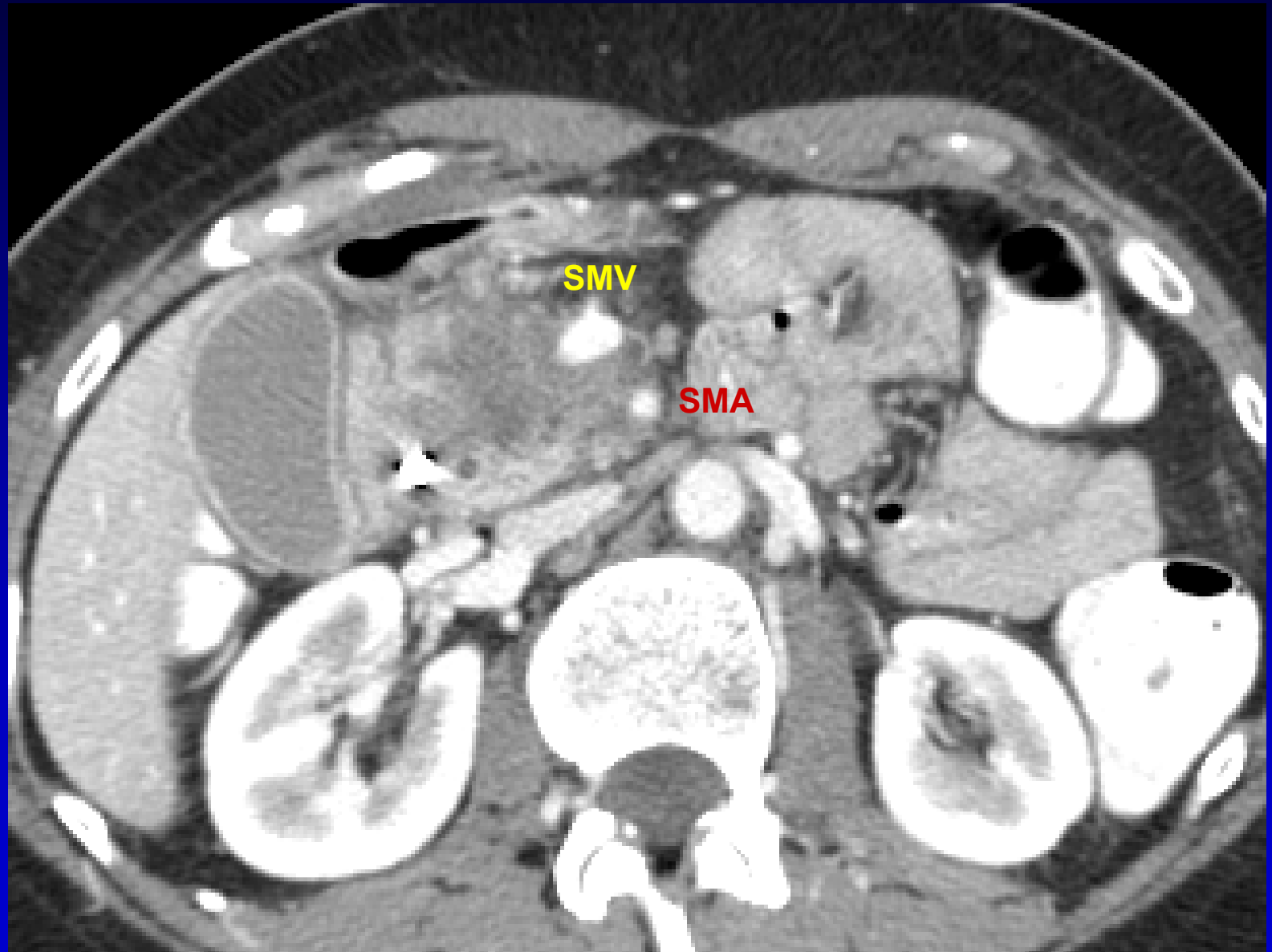
# Borderline Resectable



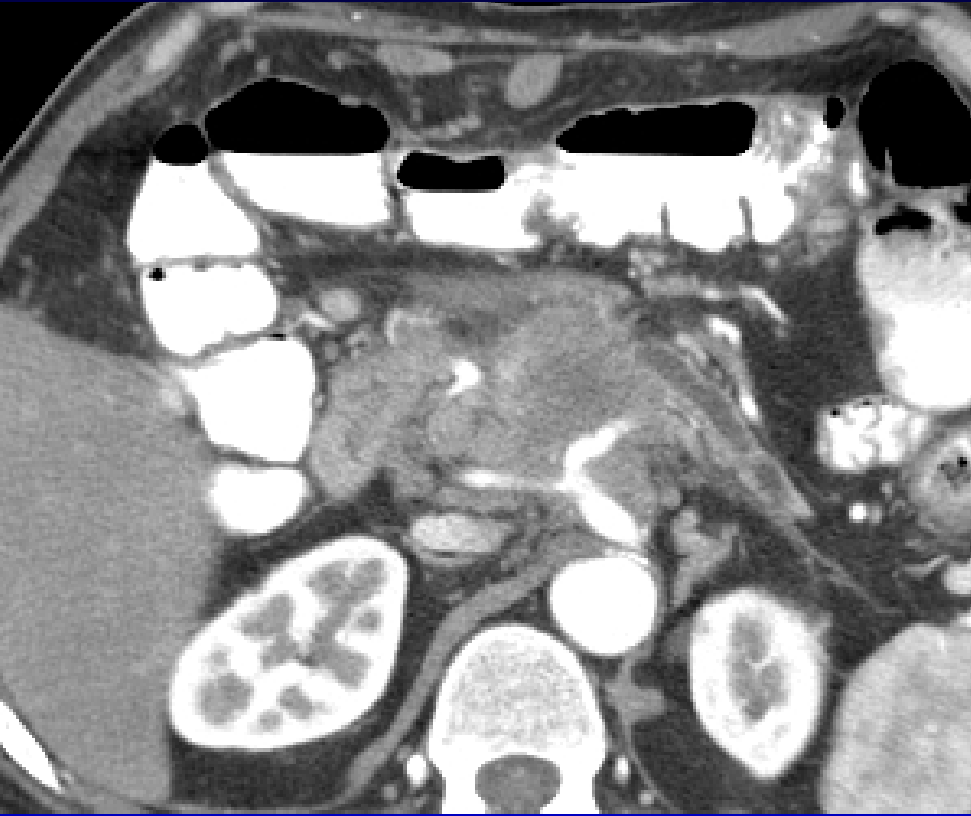Varadhachary GR, et al. Ann Surg Oncol. 2006;13(8):1035-46

Katz MHG, et al. J Am Coll Surg. 2008;206(5):833-46

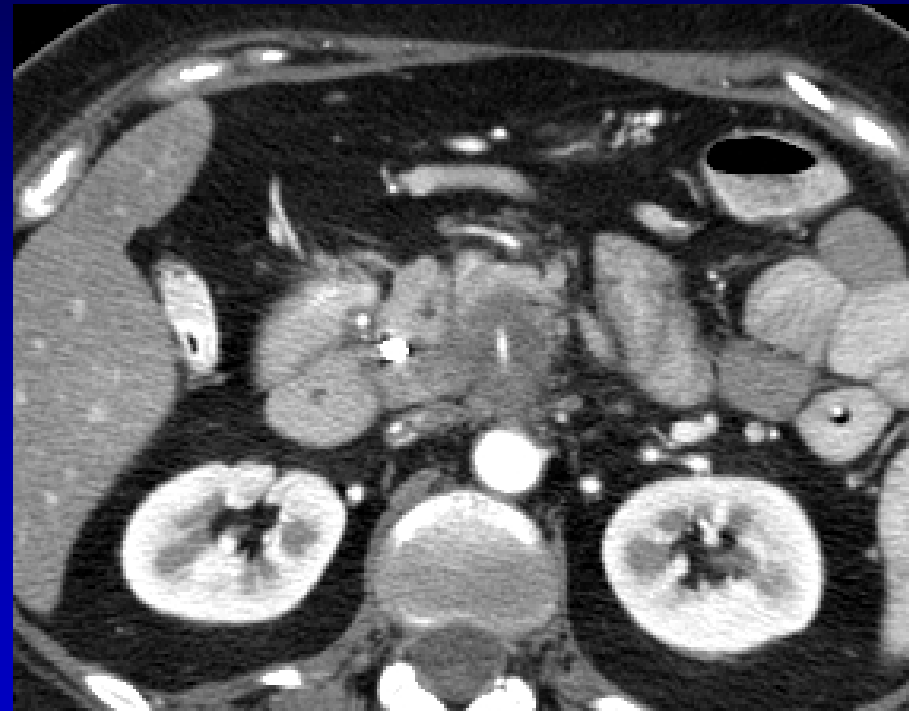# Locally Advanced (Stage III)



# Locally Advanced (Stage III)



Celiac encasement



SMA encasement

# Definitions: SSO/AHPBA CC

## Resectable:

no extension to celiac, CHA, SMA, SMV-PV  
confluence  
stage I, II (T1-3, Nx, M0)

## Borderline:

- a) venous abutment or encasement (with option for reconstruction)
- b) arterial abutment ( $\leq 180^\circ$ )

## Locally Advanced:

celiac, SMA encasement ( $> 180^\circ$ )  
stage III (T4, Nx, M0)

# Imaging Template for Pancreatic Cancer

- Tumor size and location
- Tumor and veins relationship – SMV, portal vein and splenic vein
- Tumor and arteries relationship – SMA, celiac axis, common hepatic artery
- Presence or absence of distant metastases – liver, lung, peritoneum

MDACC Multidisciplinary Pancreatic Cancer Study Group

# MDACC Classification System for Borderline Resectable Disease

- Type A: Anatomically *borderline* resectable tumor (tumor abuts artery for  $\leq 180^\circ$ )
- Type B: *Indeterminant* extrapancreatic metastasis
- Type C: Patient of *marginal* performance status

# Treatment of Borderline Resectable Pancreatic Cancer

## Underlying hypothesis / assumption

---

1. Neoadjuvant treatment sequencing used to:
  - select those with favorable biology
  - treat radiographically occult M1 disease
  - enhance the chance of a complete (R0, R1) resection
2. Outcome for R1 different than R2 (ie, better)

# Accurate Pathology and Multimodality Therapy

## Pancreaticoduodenectomy: Ductal Adenocarcinoma

### M D Anderson (N = 360)

Variable	No. Pts	Med Sur	p value
Overall	360	25	
N0	174	32	
N1	186	22	
R0	300	28	
R1	60	22	
Maj Comp			
No	263	27	
Yes	93	22	

R0 17 mo  
R1 11 mo

ESPAC-1  
Ann Surg 2001

Raut, Ann Surg 2007;246:52-60  
Local Failure (All pts): 8%

# The Importance of Neoadjuvant Therapy

Pancreaticoduodenectomy: Ductal Adenocarcinoma

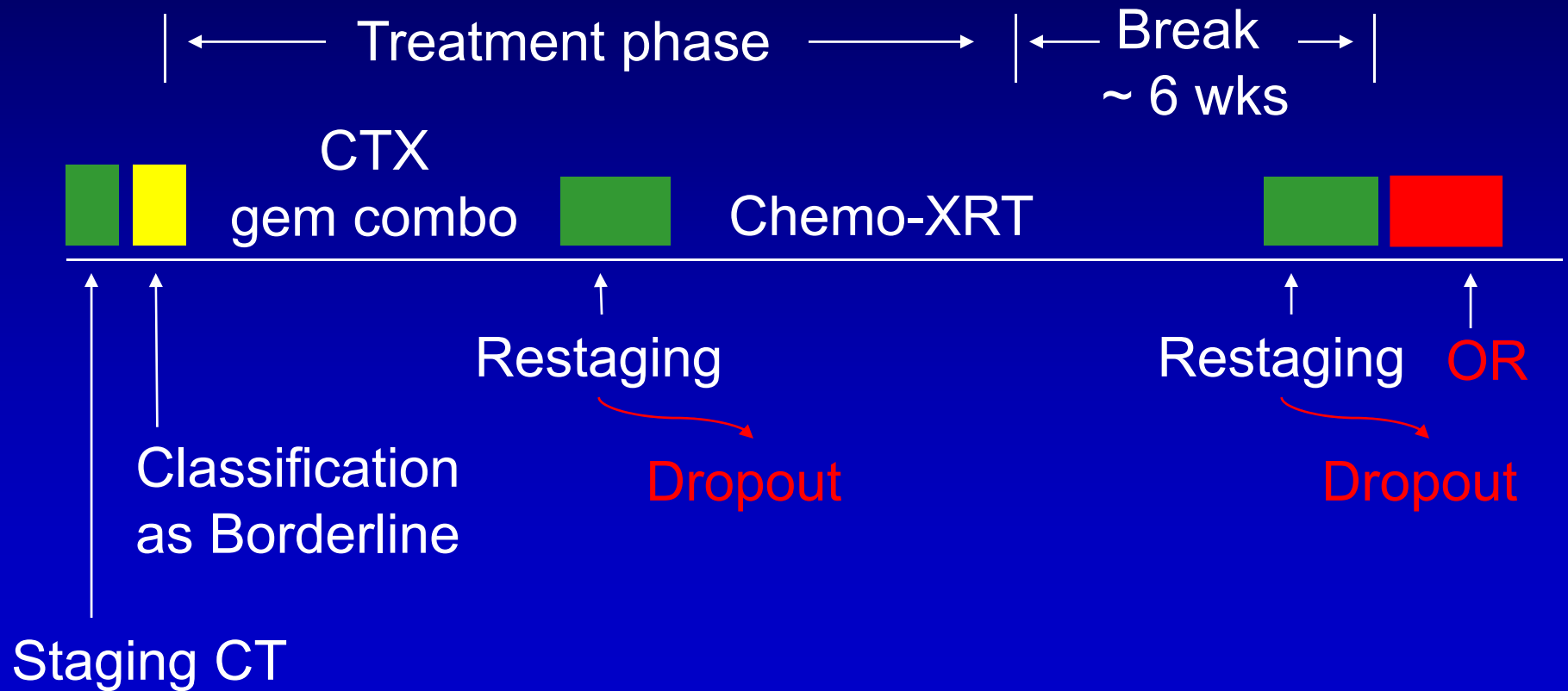
M D Anderson (N = 360)

Preoperative Therapy	R1 Resection
YES	13%
NO	19%

Raut, Ann Surg 2007;246:52-60

Local Failure (All pts): 8%

# Borderline Resectable PC MDACC Treatment Approach



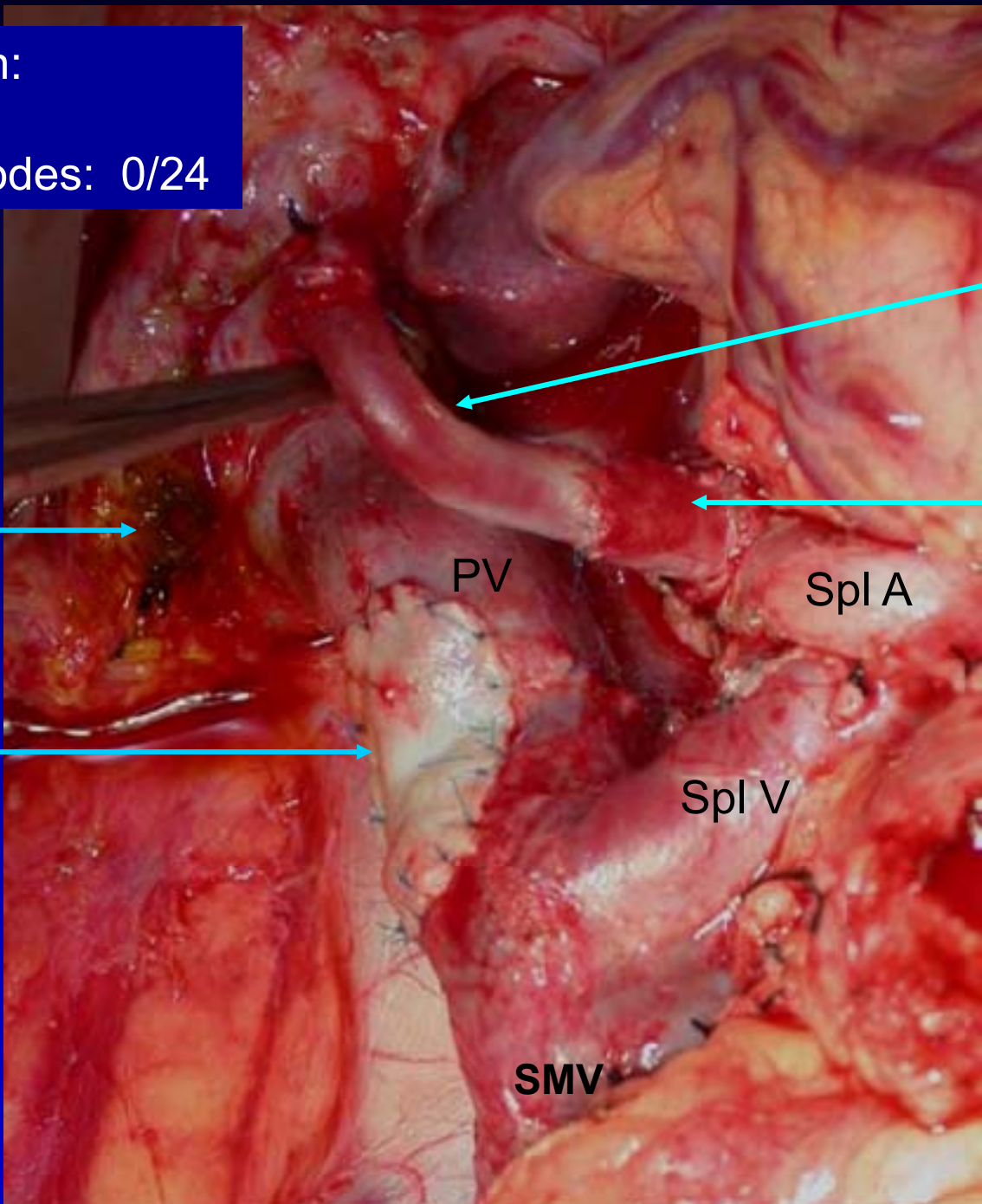
# Rates of Resection, Path Response, Survival

## 160 Patients with Borderline Resectable PC

MDACC Type	No. of Patients (%)			Median Survival (Mos)			p*
	Total	Resected	Path Resp. IIb, III, IV	All Pts	Resected	Unresected	
<b>A</b>	84 (53)	32 (38)	19 (59)	21	40	15	0.001
<b>B</b>	44 (28)	22 (50)	13 (59)	16	29	12	0.001
<b>C</b>	32 (20)	12 (38)	5 (42)	15	39	13	0.009
<b>Total</b>	<b>160</b>	<b>66 (41)</b>	<b>37 (56)</b>	<b>18</b>	<b>40</b>	<b>13</b>	<b>0.001</b>

\*p: comparison of median survival between resected and unresected patients of each type

Final path:  
R0  
Lymph nodes: 0/24



Rev saph  
vein graft

CHA

divided  
bile duct

PV

Spl A

saph vein  
patch

Spl V

SMV

## Summary

- Local tumor resectability is best determined by high quality CT (exploratory surgery is outdated)
- Resectable tumors may be treated with upfront surgery or a neoadjuvant approach
- Borderline resectable tumors are best treated with upfront systemic therapy/chemoradiation
- Locally advanced tumors, as defined by arterial encasement, are not resectable and surgery is not a realistic treatment option